


**PRESENTING CLINICAL SIGNS**

History: Grade VI/VI murmur. Coughing. Cardiomegaly. Fainted after having a bowel movement.  
 Started on furosemide and pimobendan.

**DATE**

4/13/22

**ECHOCARDIOGRAPHIC FINDINGS**

2D, M-mode, and Doppler study.

**PERFORMED BY:**

Tasha

There is mild left atrial dilation. The mitral valve leaflets are thickened and exhibit systolic prolapse. There is Doppler evidence of mitral regurgitation present. There is mild left ventricular dilation. Left ventricular systolic function is hyperdynamic. The aorta and aortic valve appear normal. Right atrial and right ventricular dimensions are normal. The tricuspid valve appears normal. The pulmonary artery and pulmonic valve appear normal. No pericardial effusion or cardiac masses are seen.

**INTERPRETED BY**

 Keith Blass, DVM,  
 MS, DACVIM  
 (Cardiology)

LA - 30.3 mm  
 LVIDd - 28.0 mm  
 LVIDs - 15.2 mm  
 FS - 45.7%

**PATIENT**

Bacon Dismey

**ASSESSMENT/RECOMMENDATIONS**

Degenerative mitral valve disease

**SPECIES**

Canine

This examination demonstrates regurgitation of blood across Bacon's mitral valve resulting from degenerative valve disease. Secondary to her regurgitation, Bacon has mild dilation of both her left atrium and left ventricle, though her left ventricular systolic function is well-preserved. While I haven't seen Bacon's radiographs, the presence of only mild left heart chamber dilation suggests that her mitral valve disease is not the primary cause of her cough. As for Bacon's fainting episode, the temporal association between defecating and fainting suggests that the episode was vasovagal in nature.

**BREED**

Shih Tzu

Continued use of pimobendan is warranted based on this exam. As for furosemide, continued use would be warranted if the medication has improved Bacon's cough.

**SEX**

FS

A recheck echocardiogram is recommended in 9 months. Repeat thoracic radiographs are recommended if Bacon's cough worsens, or she experiences an increased respiratory rate/effort.

**AGE**

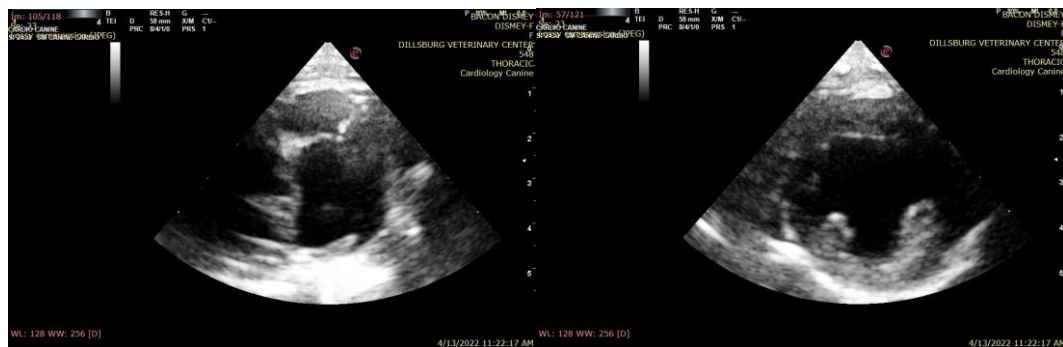14 y

**WEIGHT**

15 lb

**HOSPITAL NAME**

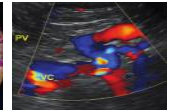
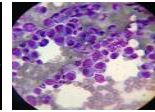
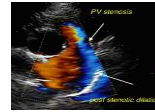
Dillsburg VC



The information and recommendations provided are based on the images presented by the referring veterinarian. No evaluation can be communicated regarding pathology that was not visible in the image/video clips provided.

**REFERRING VET**

Dr. Jacobs



Thank you for this referral. If the clinical or image interpretation does not parallel your findings or if I can be of any further assistance please contact me.

**DATE**

4/13/22 **Keith Blass, DVM, MS, DACVIM (Cardiology)**  
KeithBlass@gmail.com  
631-804-5754

**PERFORMED BY:**

Tasha

**INTERPRETED BY**

Keith Blass, DVM,  
MS, DACVIM  
(Cardiology)

**PATIENT**

Bacon Dismey

**SPECIES**

Canine

**BREED**

Shih Tzu

**SEX**

FS

**AGE**

14 y

**WEIGHT**

15 lb

**HOSPITAL NAME**

Dillsburg VC

**REFERRING VET**

Dr. Jacobs